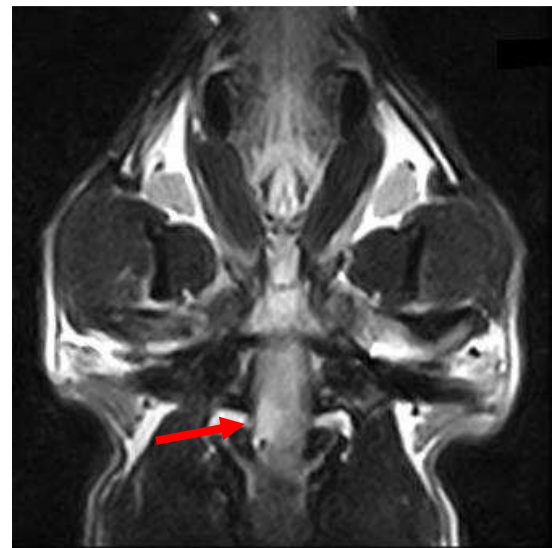
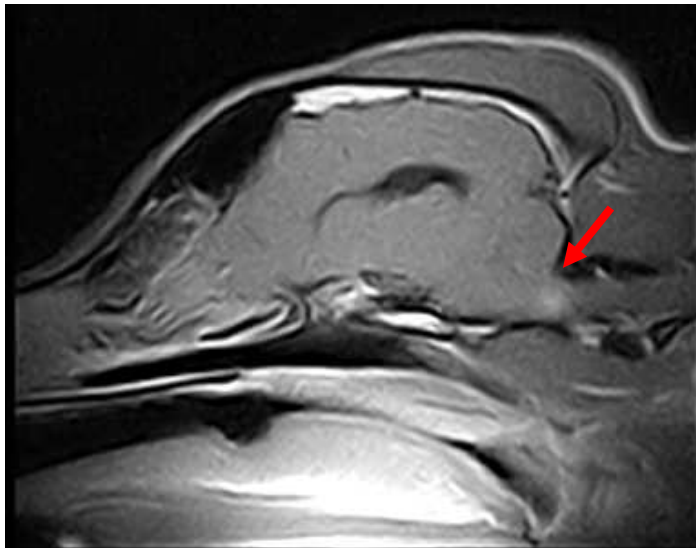
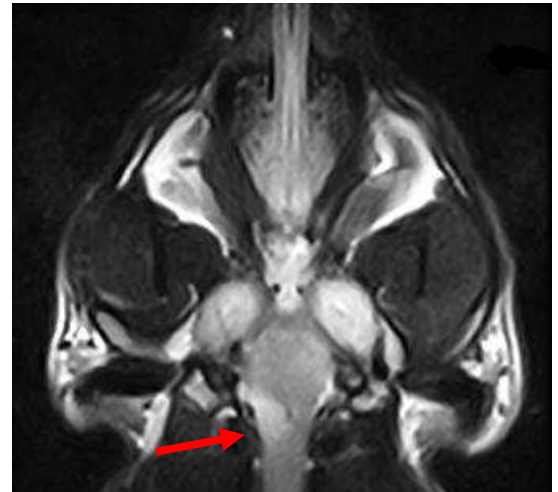




Right Brainstem Mass



A 2 year old Glen of Imaal female dog was found to be non-weight bearing on all 4 legs, pain in all 4 limbs, head down and tilts to the right, and a gait to the left. A MRI was ordered to rule out the neurological abnormalities.



Findings:

- 1) In the right brainstem, at the level of the occipital foramen, the MRI exhibits subtle contrast enhancement. The adjacent bone is unremarkable. There is a subtle leftward shift of the caudal fourth ventricle and central canal.

Conclusion:

- 1) Right brainstem mass. Considered neoplasia, granuloma or less likely abscess.

