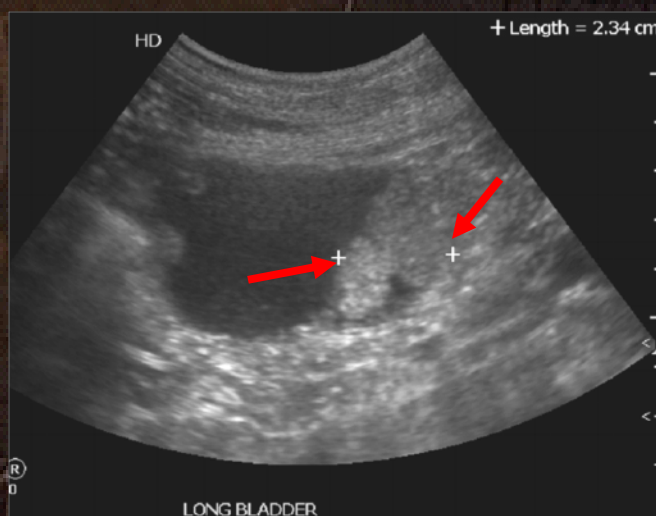


# Urinary Bladder Transitional Cell Carcinoma

A n 8 year old Sheltie dog has hematuria for 20 plus months with difficulty urinating. An ultrasound is ordered to evaluate the bladder.



## Findings:

Probable transitional cell carcinoma of the bladder and urethra with skip metastases within the bladder wall. No evidence of spread to local lymph nodes at this time (medial iliac LN) or urethral obstruction.

Dr. Sophie Dennison, BVM&S, Diplomate ACVR  
Sam Silverman DVM and Associates



Advanced Animal Imaging

