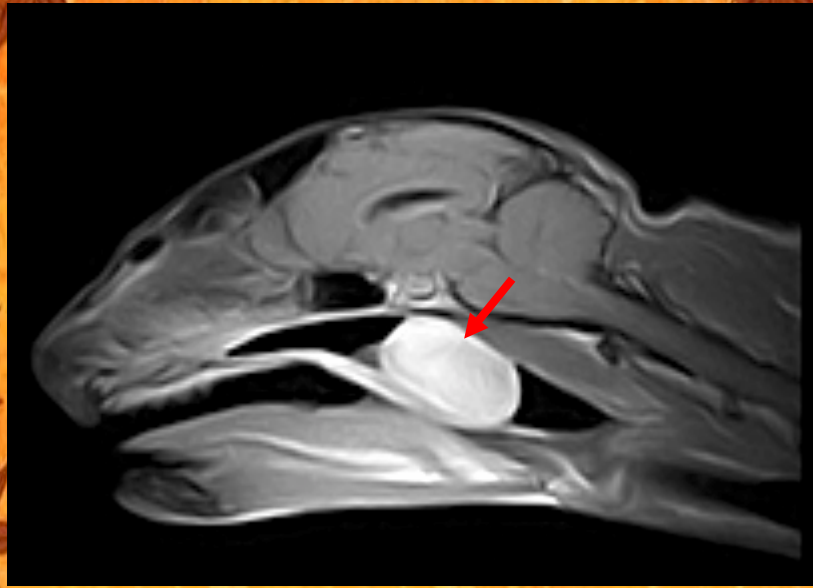




# Nasopharyngeal Mass

A 16 month old feline has been on antibiotics for several months. The patient has labored breathing sounds, coughs and sneezes frequently. All of these symptoms occurred since birth and now an MRI was ordered.




## Findings:

A 1.2 by 1.5 by 2.3 cm ovoid mass in the nasopharynx that is somewhat right-sided.

## Conclusion:

Nasopharyngeal mass with probable right bulla component; however, the right bulla abnormalities could be due to obstructive otitis media. In this age patient, the most likely differential is an inflammatory (nasopharyngeal) polyp.



Dictated By:

Dr. Tsuyoshi Murakami, DVM, PhD, DACVR  
Ohio State University



Advanced Animal Imaging

