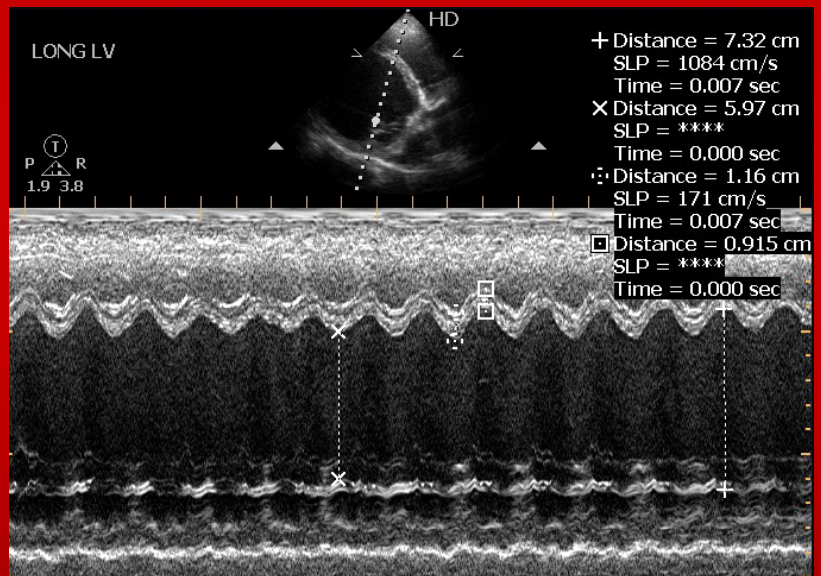
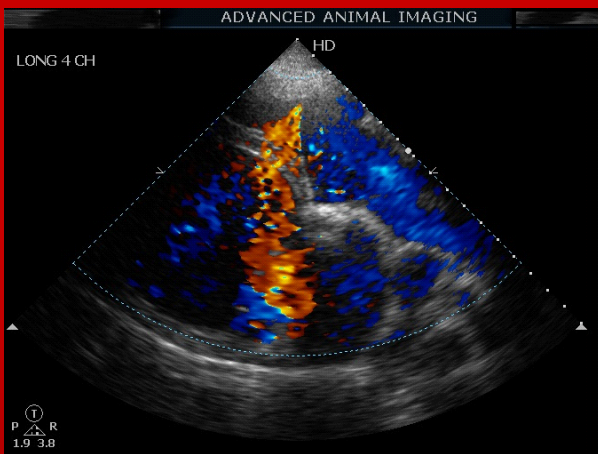




# Cardiomyopathy



**A 6 year old female St. Bernard dog has heavy breathing and coughing. Echocardiography was ordered to evaluate her heart and find the probable cause.**



## Findings:

- 1) Severe left ventricular dilation with thin walls and systolic dysfunction is consistent with dilated cardiomyopathy. There are degenerative changes to the mitral valve with mild insufficiency detected. The left atrium is severely dilated consistent with left-sided congestive heart failure.

Dr. Brian MacKie DVM, DACVIM (Cardiology)



**Advanced Animal Imaging**

