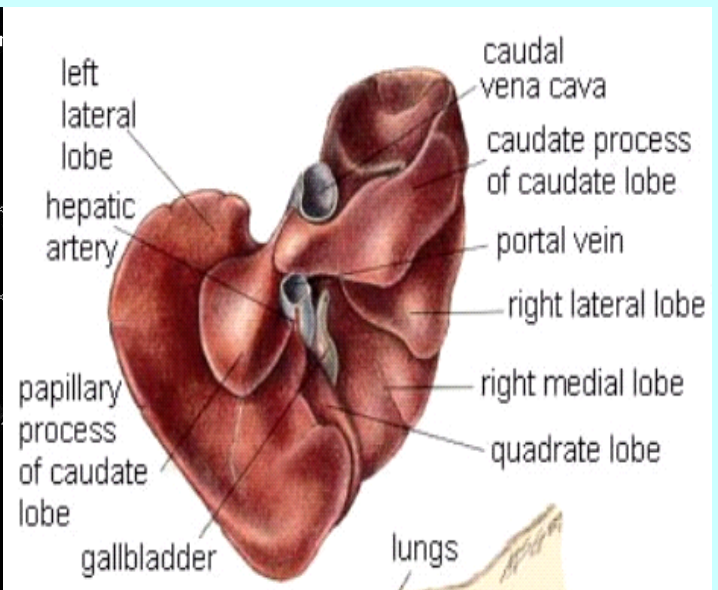
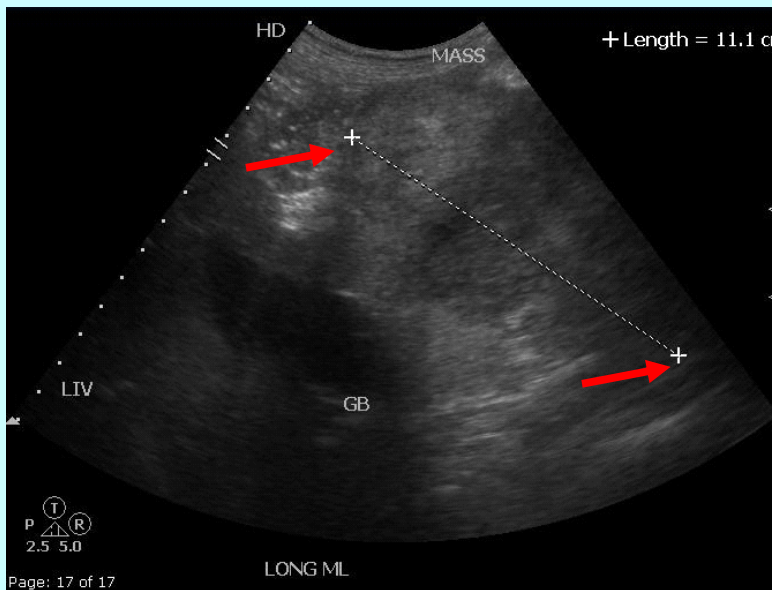





# Neoplastic Hepatic Mass



An 11 year old male Golden Retriever dog has an increase for thirst and frequent urination. Labs demonstrated elevated liver enzymes. Palpitations of the abdomen felt firm in the liver and spleen region.



## Findings:

- 1) Hepatic Mass with at least two hepatic nodules is most consistent with neoplasia. Resection may be possible but the additional nodules should also be sampled, if possible, to rule out metastatic disease.

Dr. Sophie Dennison BVM&S, Diplomate ACVR (Sam Silverman DVM and Associates)



Advanced Animal Imaging

