




Cranial Cruciate Ligament Rupture



Freckles
Brittany Spaniel
6 Year Old Neutered Male

While running in the field the owner noticed a right back leg injury. Freckles became non weight bearing and was seen by a veterinarian who recommended medication. After some time, the medication didn't resolve the problem and an MRI exam was performed.

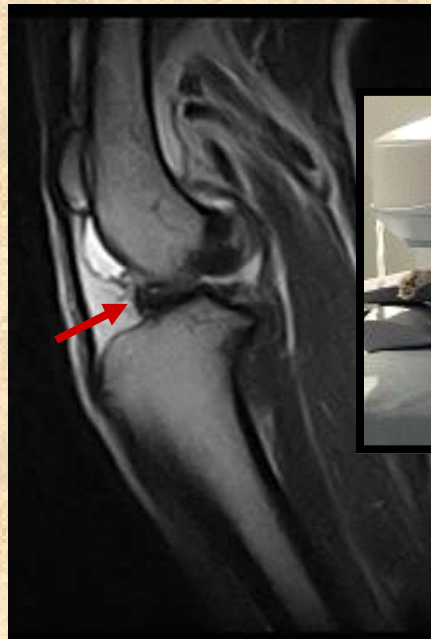
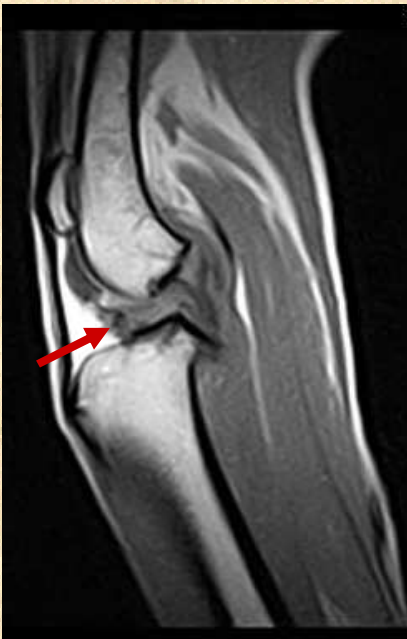
Photo by Ellie Bogue

Findings:

1. Cranial cruciate ligament ruptured with resultant stifle joint effusion and subchondral bone edema.
2. Long digital extensor tendinitis and myositis.



Advanced Animal Imaging

