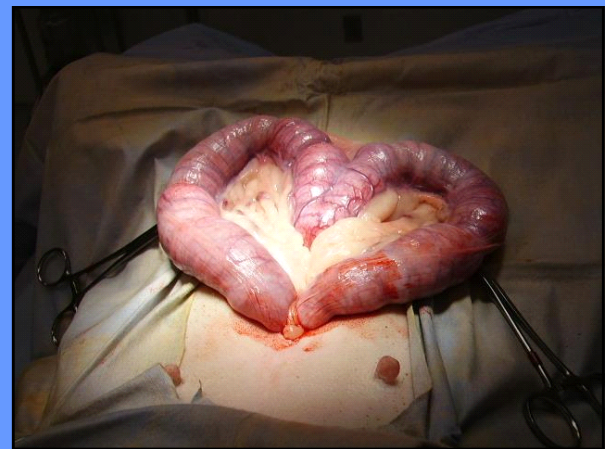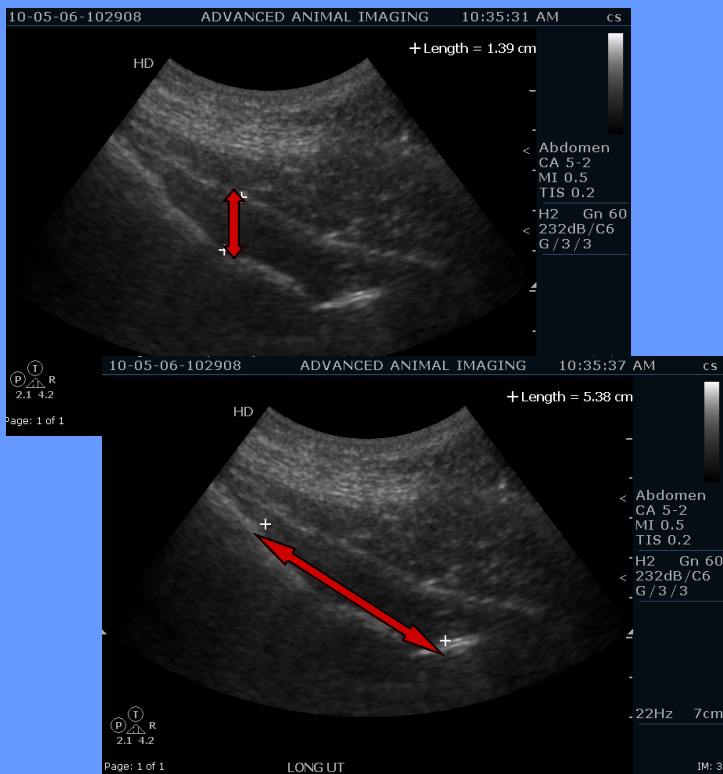


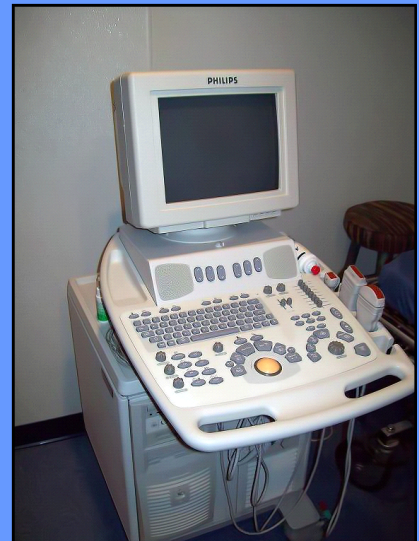Pyometra



Molly Golden Retriever 5 Year Old Female

Molly was presented with discharge, loss of appetite, increase in thirst, and a frequency in urination. An ultrasound was ordered to examine the abdomen, reproductive organs, and survey any urinary abnormalities.



Surgery Revealed Pyometra

Findings:

1. Diffuse thickening of the myometrium which measures 1.3 x 5.4 by approximately 4 cm. This appearance of the uterus would be consistent with a pyometra.

